EXAMINATION OF THE EYE

BY: DR. KAHAKI KIMANI

THE EYE IS THE LAMP OF THE WHOLE BODY.

IF YOUR EYES ARE GOOD YOUR WHOLE BODY WILL BE FULL OF LIGHT, BUT IF YOUR EYES ARE BAD YOUR WHOLE BODY WILL BE FULL OF DARKNESS (MAT. 6: 22 – 23).

EXAMINATION OUTLINE

- HISTORY TAKING
- VISUAL ACUITY TESTING
- INSPECTION
- TORCH EXAMINATION
- FUNDOSCOPY

ANATOMY

- Anterior segment
  - Conjunctiva
  - Cornea
  - Sclera
  - Anterior Chamber
  - Iris
  - Pupil
  - Posterior Chamber → between the posterior aspect of the iris and the anterior aspect of the lens
- Posterior segment
  - Vitreous humor
  - Ciliary body
  - Choroid
  - Retina
  - Optic disc

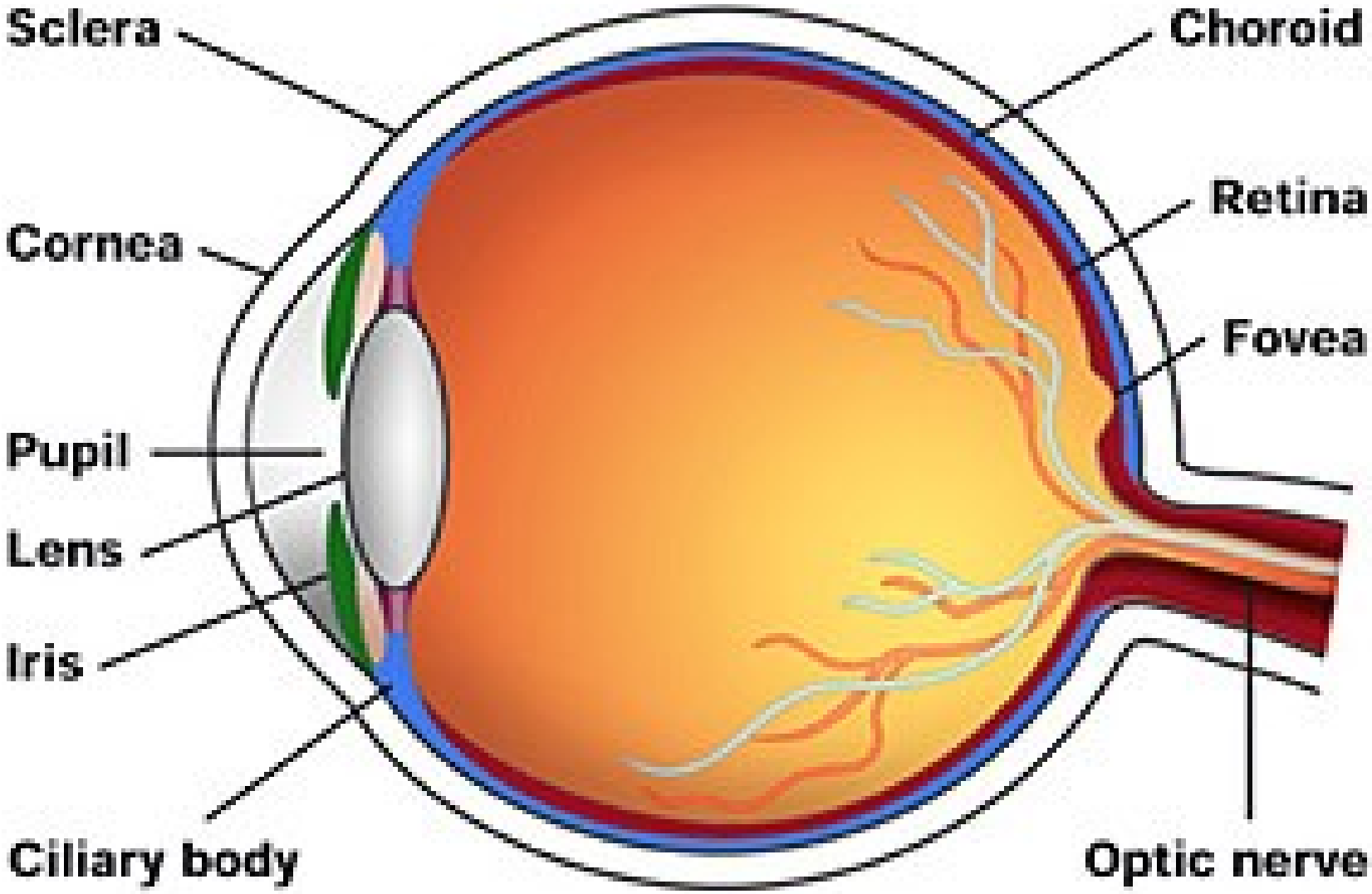
Sclera
Cornea
Pupil
Lens
Iris
Ciliary body
Choroid
Retina
Fovea
Optic nerve

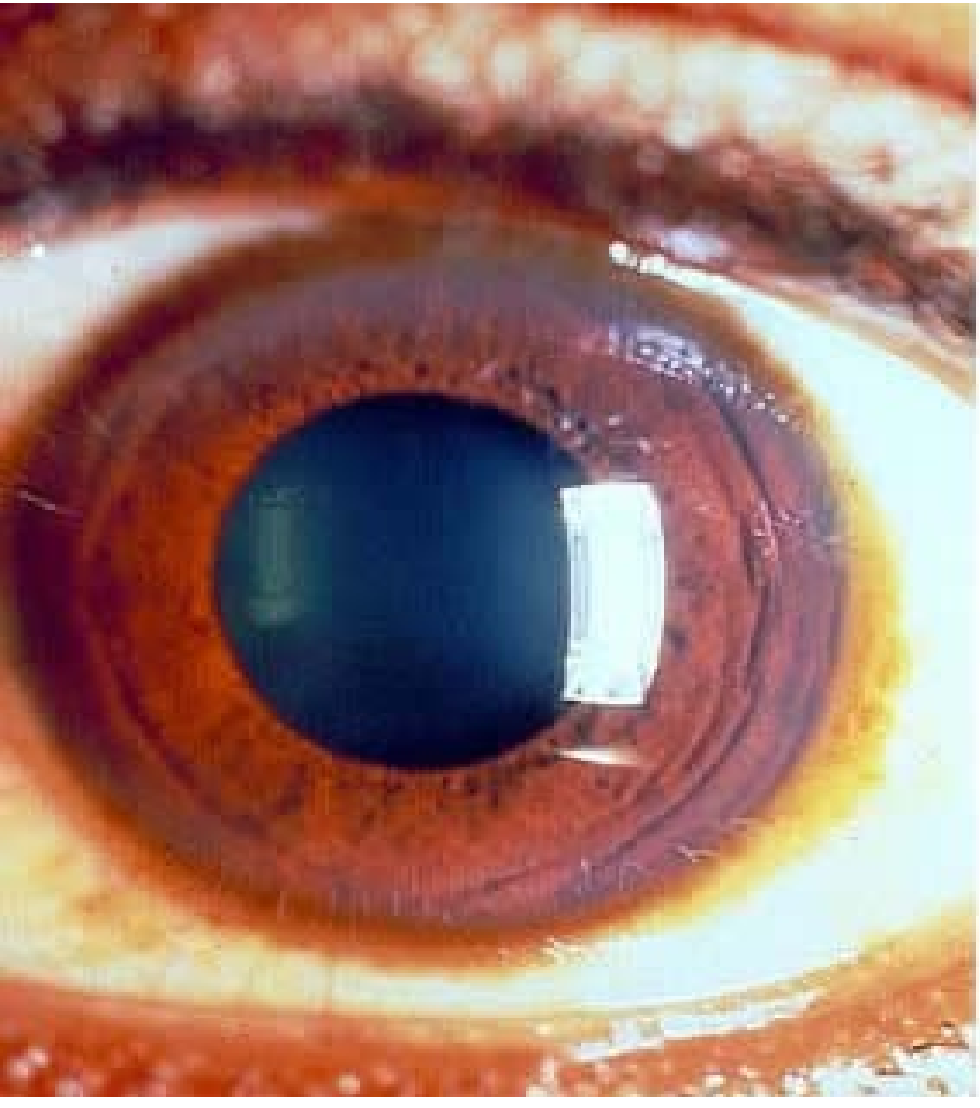

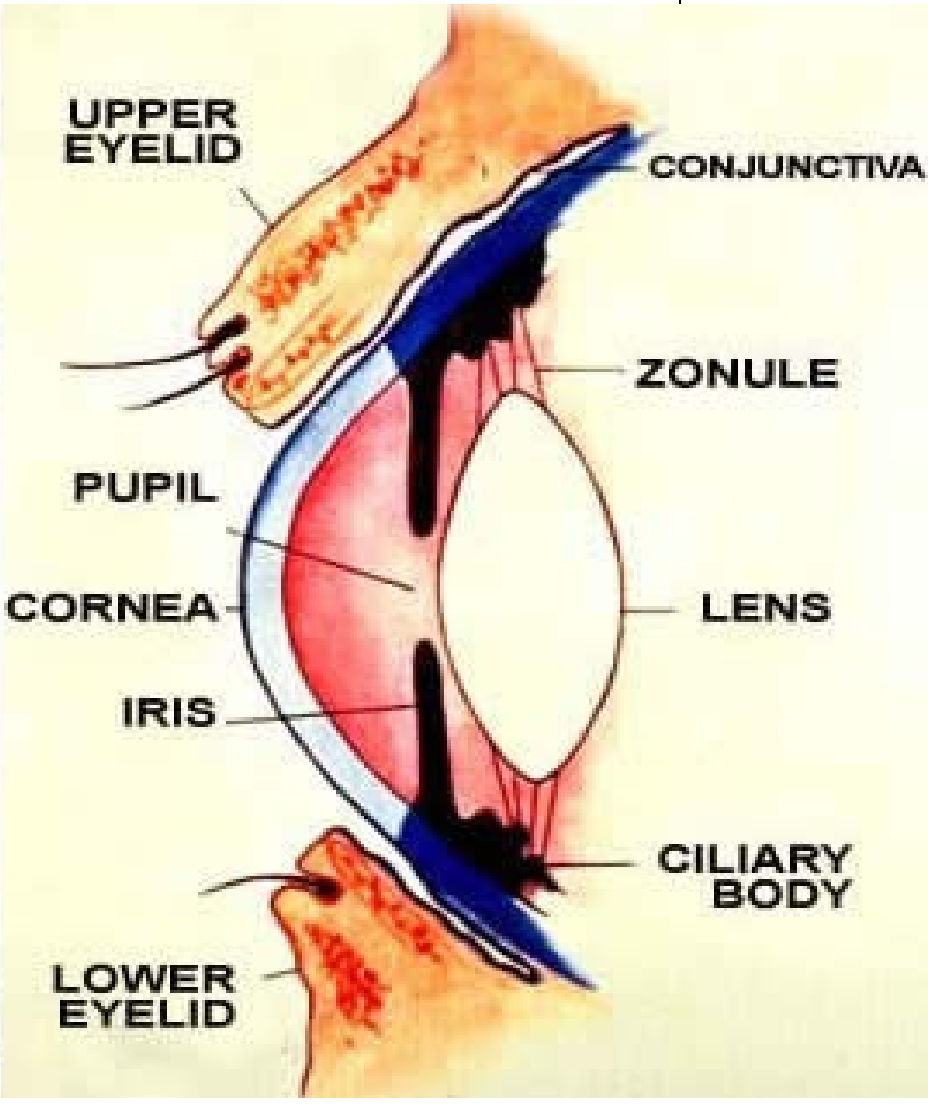
UPPER EYELID
CONJUNCTIVA
ZONULE
PUPIL
CORNEA
LENS
IRIS
CILIARY BODY
LOWER EYELID

- In order to understand diseases of the eye it is important to know about the anatomy of the eye. Look at the above picture on the left. This shows the front part of a normal eye. On the right we see a diagrammatic cut section of the front of the eye.
- The **white of the eye** as seen on the left is the main outer coat of the eye - it is called the **sclera**. Covering the front part of the sclera as well as the inner surface of the eyelids is a thin membrane called the **conjunctiva**. This membrane contains many blood vessels and becomes red when inflamed.
- At the front of each eye is a disc of clear tissue, the **cornea**. This is not seen in the photograph on the left because it is transparent, but it is clearly shown in the picture on the right → slightly curved and shown as pale blue in the slide.
- Behind the clear cornea is the **iris** with a circular hole in its centre. The hole is the **pupil**. The iris is seen clearly in the photograph on the left because the cornea is clear. The pupil appears black. The **sclera and the iris are opaque** → they do not allow light to pass through them. Light enters the eye through the clear transparent cornea and then passes through the pupil.
- Between the cornea and the iris is the **anterior chamber** of the eye.
- Behind the pupil is the transparent **lens**. The lens can change shape and power so that we are able to focus on both near and distant objects.

INSTRUMENTATION

- Pen torch →



Pen Light Torch

- Direct ophthalmoscope →

HISTORY TAKING

- **Biodata**
- **Presenting complaint** e.g. itching, eye-pain etc. (chronology & duration)
- **HPI**
  - Progression
  - Precipitating factors
- **Past Ocular history**
- **Past medical history**
  - Some systemic diseases can cause eye pathology
- **Current medications**
  - Ocular and systemic
  - **Ethambutol** (reduced visual acuity), **chlorpromazine** (cataracts) etc.

CONT.

- **Family and social history**
  - Myopia, retinoblastoma
- **Children → antenatal, birth and developmental history**
  - Retinopathy of prematurity in preterm babies; birth asphyxia may result in cerebral palsy which may impair development of the occipital lobe
  - Delayed milestones?
  - Meningitis?
- **System inquiry**

EXAMINATION

1. VISUAL ACUITY
2. VISUAL FIELDS
3. INTRAOCULAR PRESSURE(GOLDMAN TONOMETER)
4. ANATOMICAL EXAMINATION
5. PUPIL REACTION
6. TORCH EXAMINATION
7. FUNDOSCOPY

VISUAL ACUITY (SNELLEN CHART)

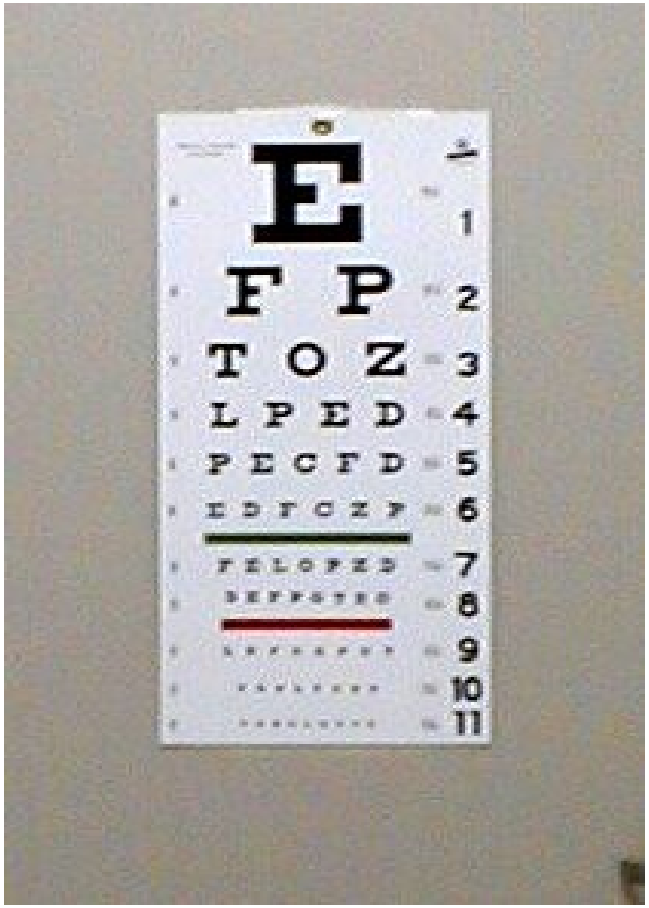

CONT.

- This is the **first thing** that is done on examining a patient.
- Take vision acuity testing for **each eye at a time**, ensuring the other eye is completely covered (**start with the right eye**).
- The normal visual acuity chart is called **the Snellen's Chart** placed at **6M** in a well-lit room.
- For driving **6/9** is the acceptable vision acuity.
- **6/5** is better than normal vision.
- For illiterate people use the **illiterate E chart;** ask them which direction are the 'legs of the E' facing.

ILLITERATE VISUAL ACUITY CHART

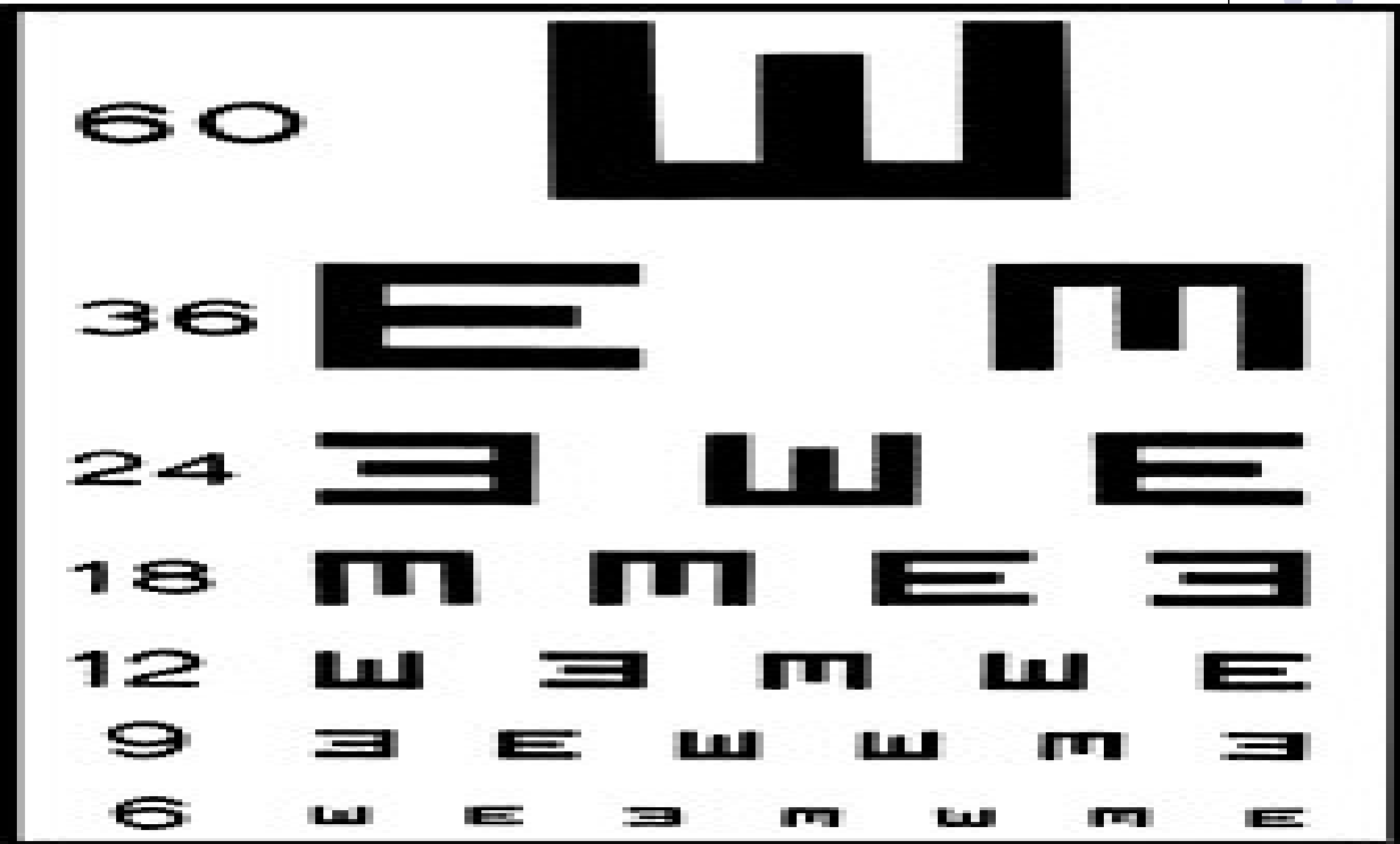

FOR VISION LESS THAN 6/60

- Counting fingers; 1-5 meters
- Hand movement
- Perception of light (PL or NPL)

RECORDING VISUAL ACUITY

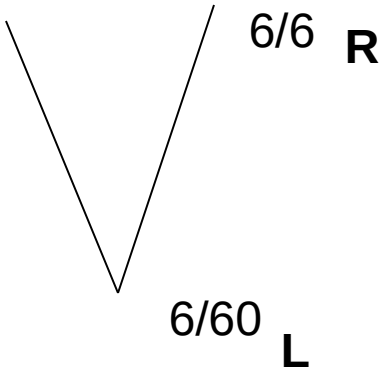

V.A= ***actual distance***

Standard distance

e.g. 6/60 : **patient reads at 6m what a normal person can read at 60m**

ANATOMICAL EXAMINATION

- **Ocular adnexa**
- **Swelling/masses**
- **Deformities**
- **Asymmetry**
- **Misalignment of the eyes**
  - Squint, strabismus, esotropia, exotropia
- **Discharge**
  - Color; consistency
  - Watery? Purulent? Mucoid?
- **Proptosis**
  - An eye that is pushed forward
- **Pupil**
- **Extra-Ocular Motility (EOM)**

OCULAR ADNEXA

- Eye brows
- Eyelids →
  - Symmetry in height? Margin of lid in relation to globe? Ectropion? Entropion? ptosis
- Lateral and medial canthus
- Conjunctiva → injection? Distribution of the redness? Discharge? Hemorrhage?
- Caruncle
- Lacrimal system

EXTRA - OCULAR MUSCLE MOTILITY

- Sit at the level of the patient
- Examine **both eyes together**
- Use your **finger** or a **bright light**
- Hold the target at **0.5 – 1m** from the face of the patient
- **Six cardinal positions of the eye**.
- Check for the vertical and horizontal recti and the obliques.
- When testing the obliques, the eye should be in **abduction**.
- Record:
  - Position of the eyes
  - Range of eye movements
  - Type of eye movements

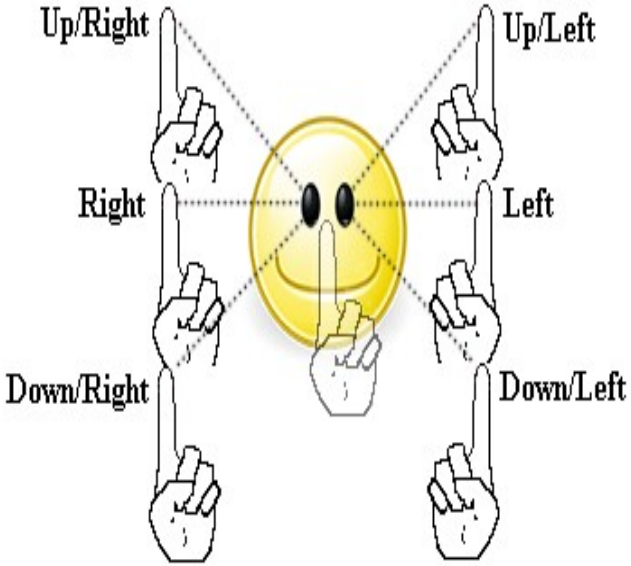

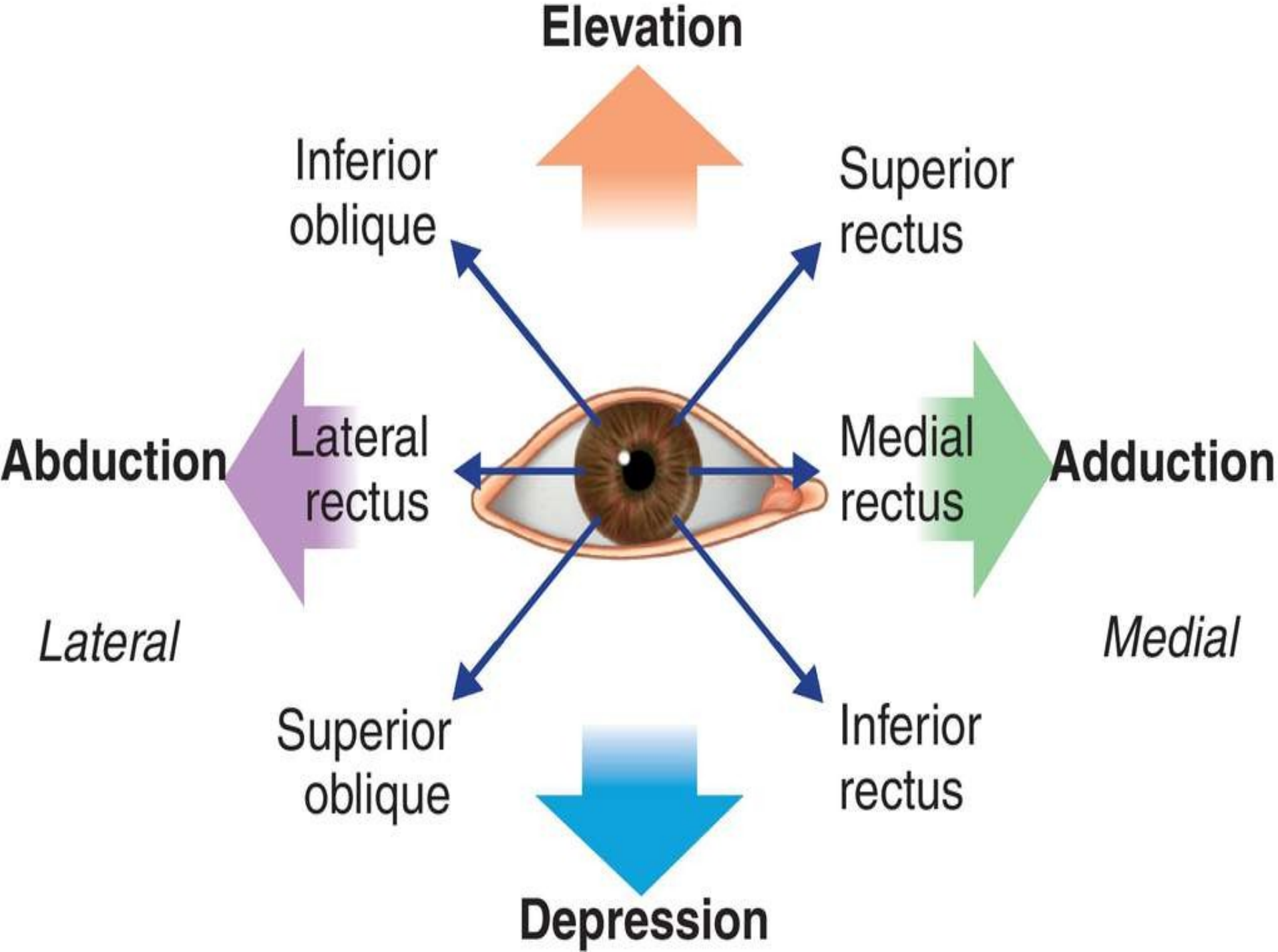
Elevation
Inferior oblique
Superior rectus
Abduction
Lateral rectus
Medial rectus
Adduction
Lateral
Medial
Superior oblique
Inferior rectus
Depression

ANATOMICAL EXAMINATION

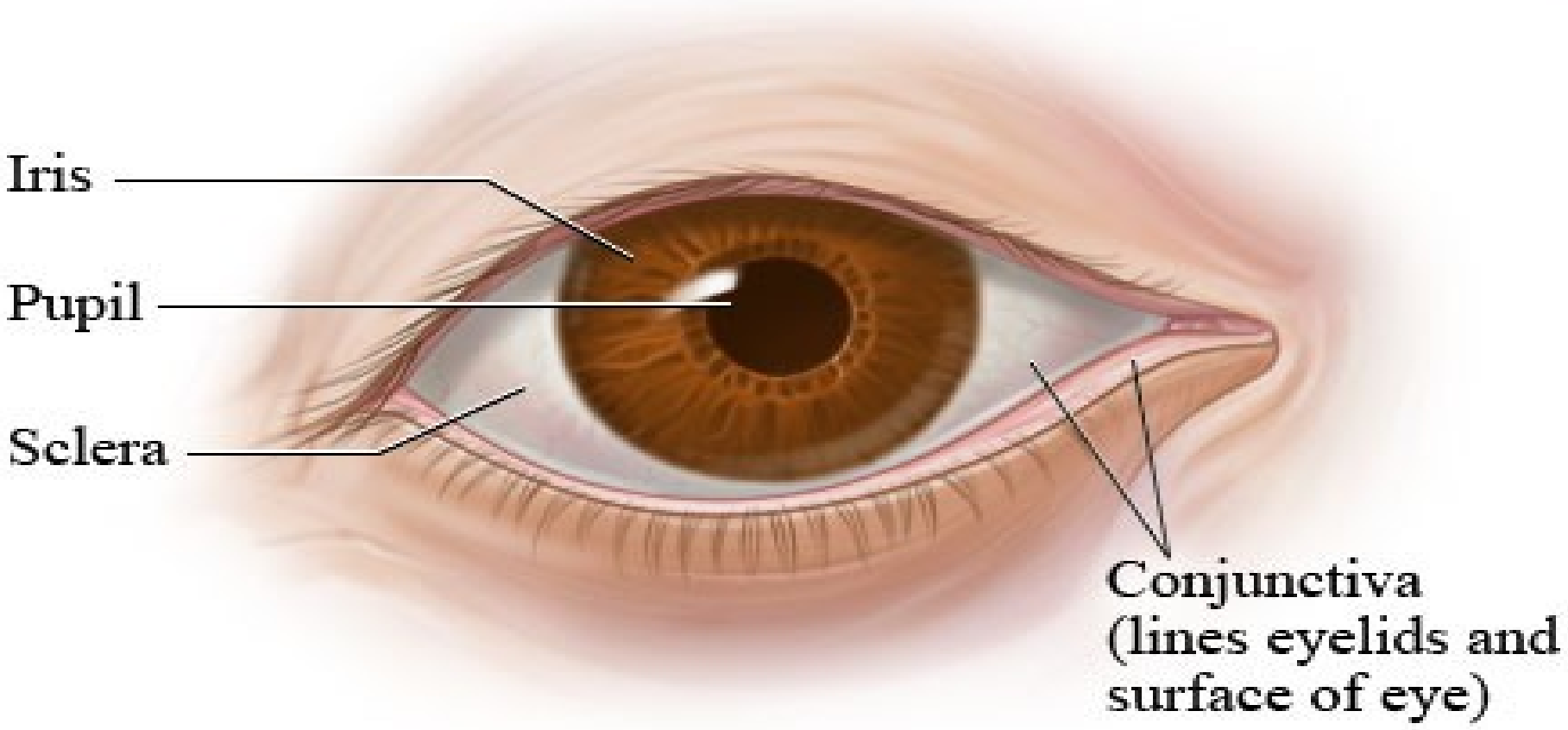

© Healthwise, Incorporated

ESOTROPIA

EXOTROPIA

CONJUNCTIVA: EVERSION OF THE EYELID

- These two pictures show an important technique in eye examination.
- It is necessary to routinely **evert the upper eyelid** to view the papebral conjunctiva. This will reveal conditions such as **trachoma**, **allergic conjunctivitis** or a **foreign body** which is hidden behind the upper eyelid.
- A gentle approach is required. **Do not carry out this procedure if there has been a penetrating injury of the eye or if the cornea is thin due to ulceration**. Pressure on the eyeball during this technique could cause the eye contents to come out in the presence of a penetrating injury or deep corneal ulceration.
- With the patient looking down, but not with the eyes closed, gently hold the eyelashes between finger and thumb. Place a small object against the outside of the upper part of the eyelid - a cotton wool bud or your thumb will be fine. Turn the eyelid using steady and gentle pressure on the upper eyelid and the eyelid will quickly evert. The eyelid will return to its normal position if the patient looks up.

CONT.

- **Sub-tarsal foreign body**

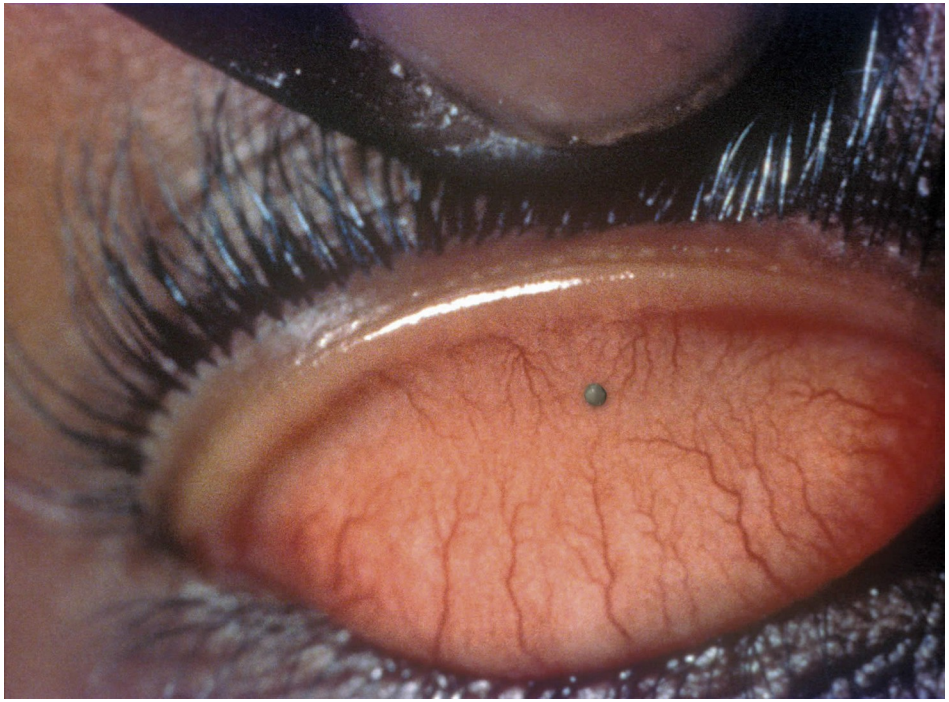

ANTERIOR CHAMBER: HYPHAEMA VS. HYPOPYON

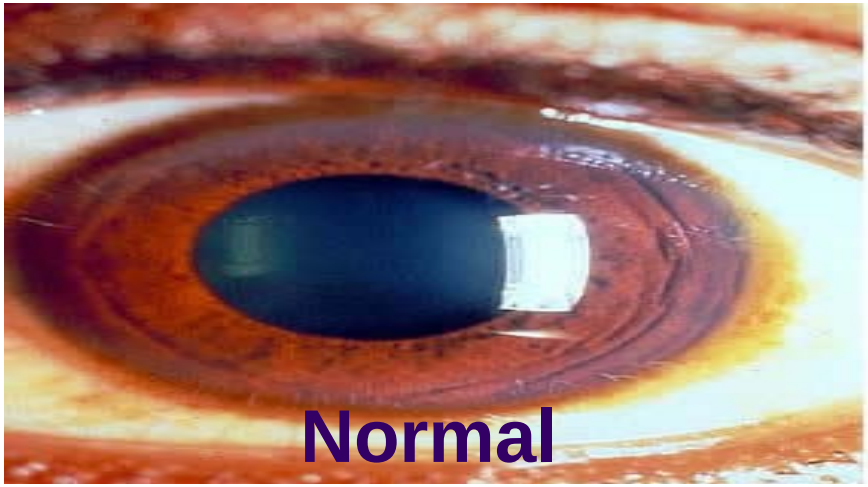

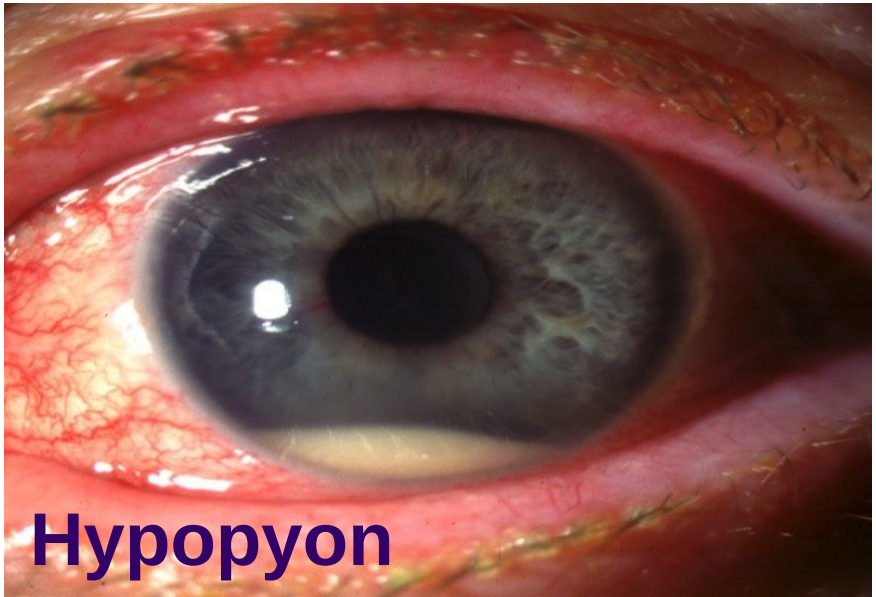

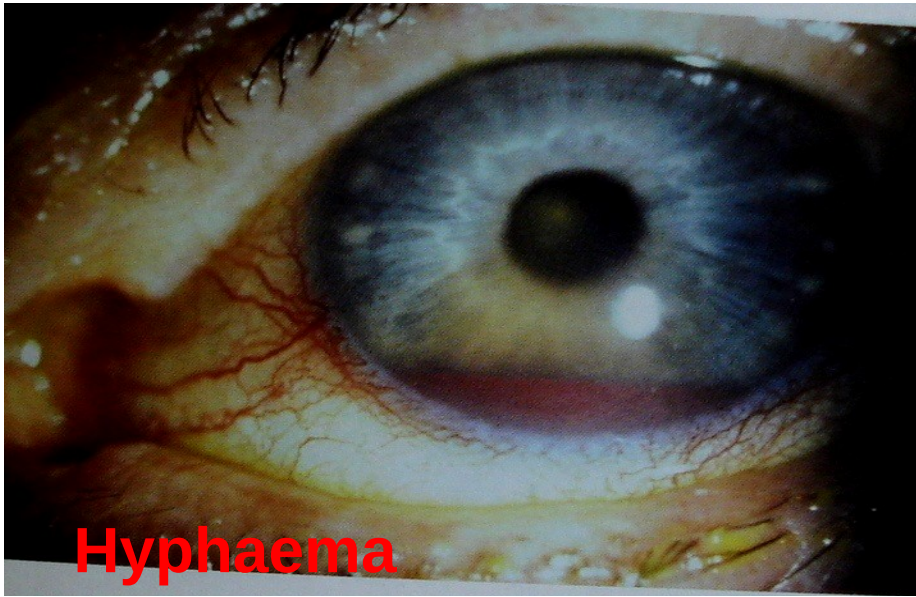

THE PUPIL

PUPIL EXAMINATION: CONSTRICTED VS. DILATED

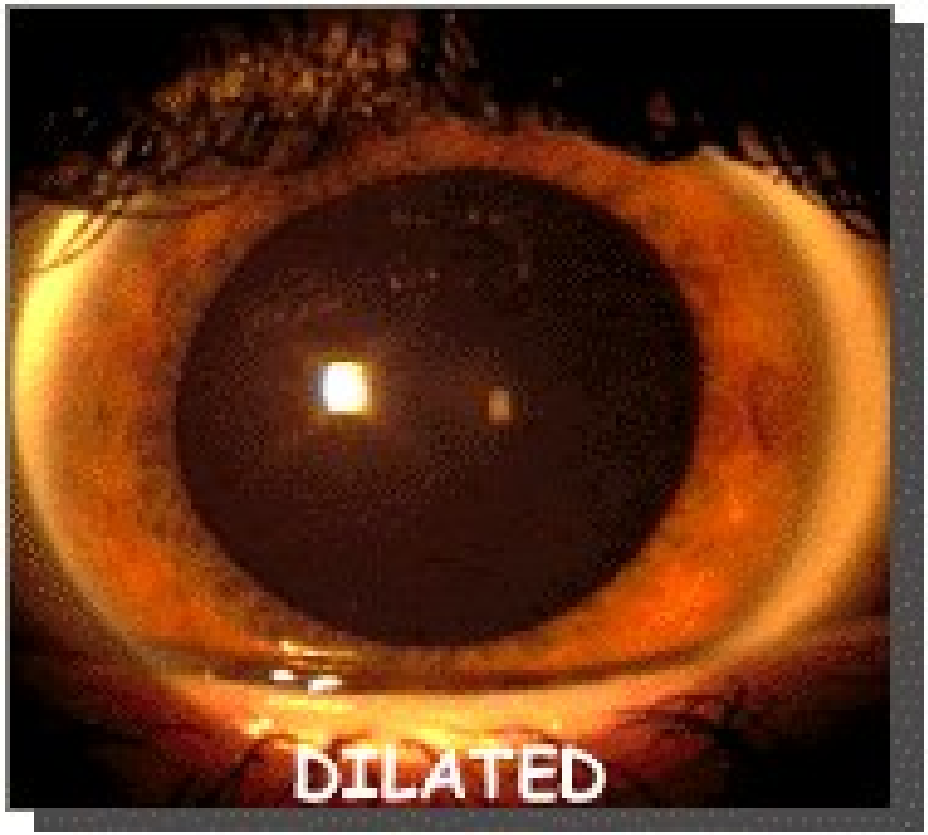

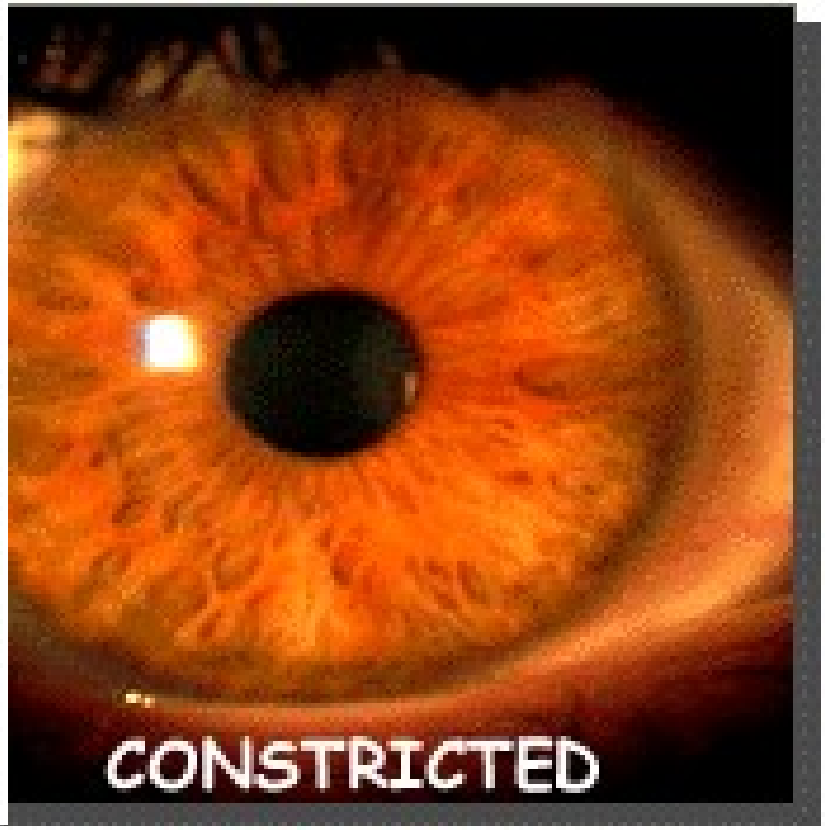

PUPILLARY REACTIONS

- Size of pupil and response to light and accommodation give important information about:
  - Function of the afferent pathway controlling pupils (Optic nerve and tract)
  - Efferent pathway
  - Action of drugs

PUPILLARY EXAMINATION

1. Assess size and symmetry in uniform light;
   - asymmetry (anisocoria) → smaller or larger pupil is abnormal?
2. Assess accommodation → look at near object (near reflex → constricition)
3. Swinging flashlight test (pupillary conduction defect, Marcus Gunn pupil)

The Pupil

- **Swing Flash Light Test**

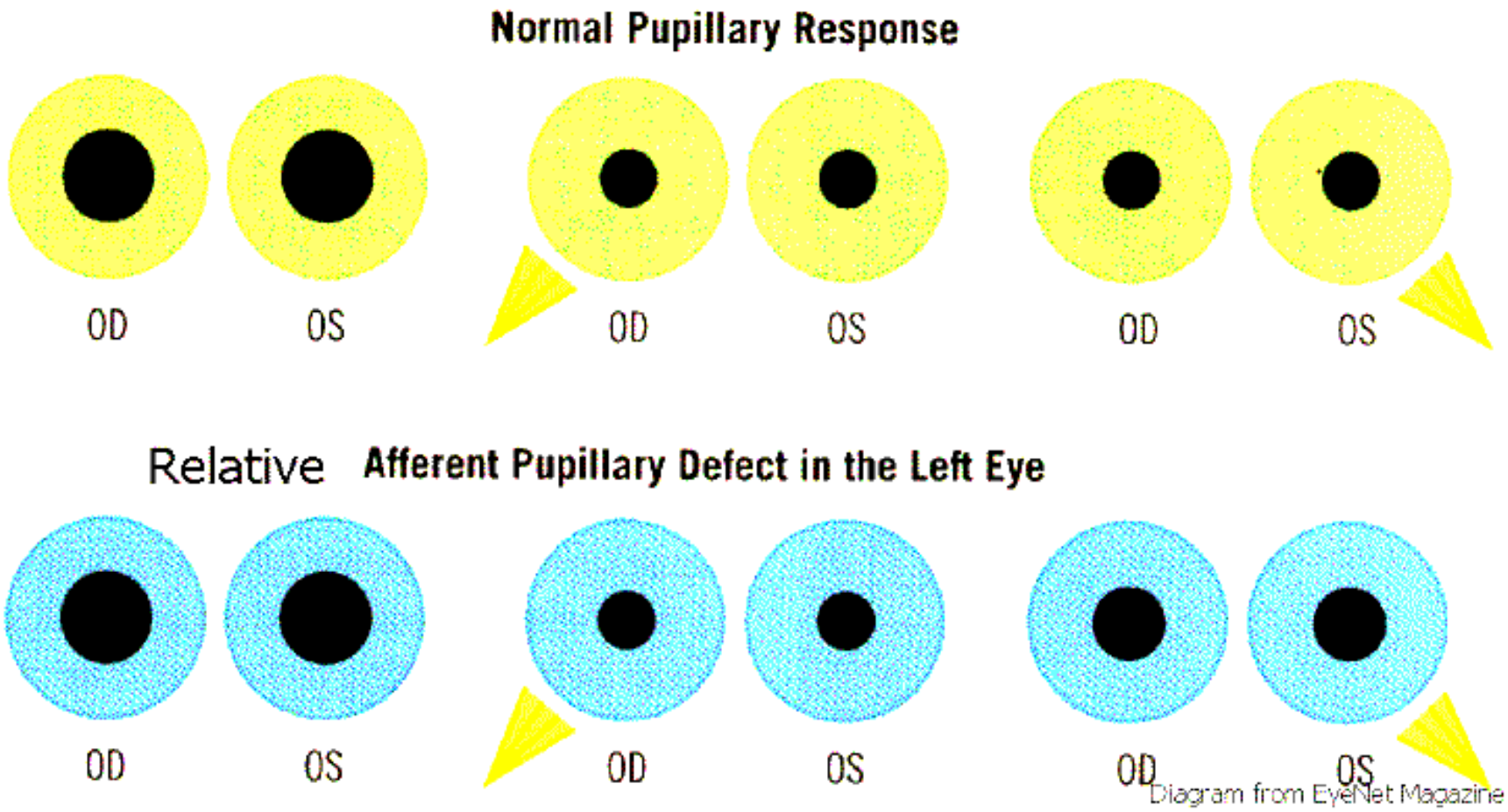

CONT.

- Direct pupillary reaction:
  - Tests the afferent pathway (Optic nerve)
- Consensual reflex
  - Look at the eye to which
  - Tests the efferent pathway (Oculomotor nerve)
- Swinging flashlight test

EXAMINATION WITH A TORCH

- Check whether the **brows** are in the normal position:
  - Facial palsy
- Are eyes aligned?
- Lids: apposition, lashes
  - Retraction (thyroid related orbitopathy)
  - Ptosis
  - Direction of the eye lashes; misdirection causes corneal ulceration as in Trachoma
- Conjunctival injection, discharge
- Cornea: clarity. Opacities
- Anterior chamber: depth, hyphaema, hypopyon
- Pupil: color, shape, size, reaction to light
- Lens
  - Should be clear; cataracts may make pupil appear white or grayish

CONT.

- Discharge and tearing
- Is the sclera white?
- Conjunctiva injection? (bulbar and palpebral/tarsal)
- Is the cornea clear?
  - Opacities?
- Is the anterior chamber clear?
  - Shine the light from the side
  - Depth (distance between the cornea and the iris)
    - Narrowed?
  - Blood in anterior chamber (hyphaemia)
  - Pus in anterior chamber (hypopion)

CONT.

- Is the pupil black and reacting normally to light?
  - Shape? Irregularities – trauma, inflammation
  - Posterior synechia
  - Dilated (topical medications, oculomotor palsy)

FUNDOSCOPY

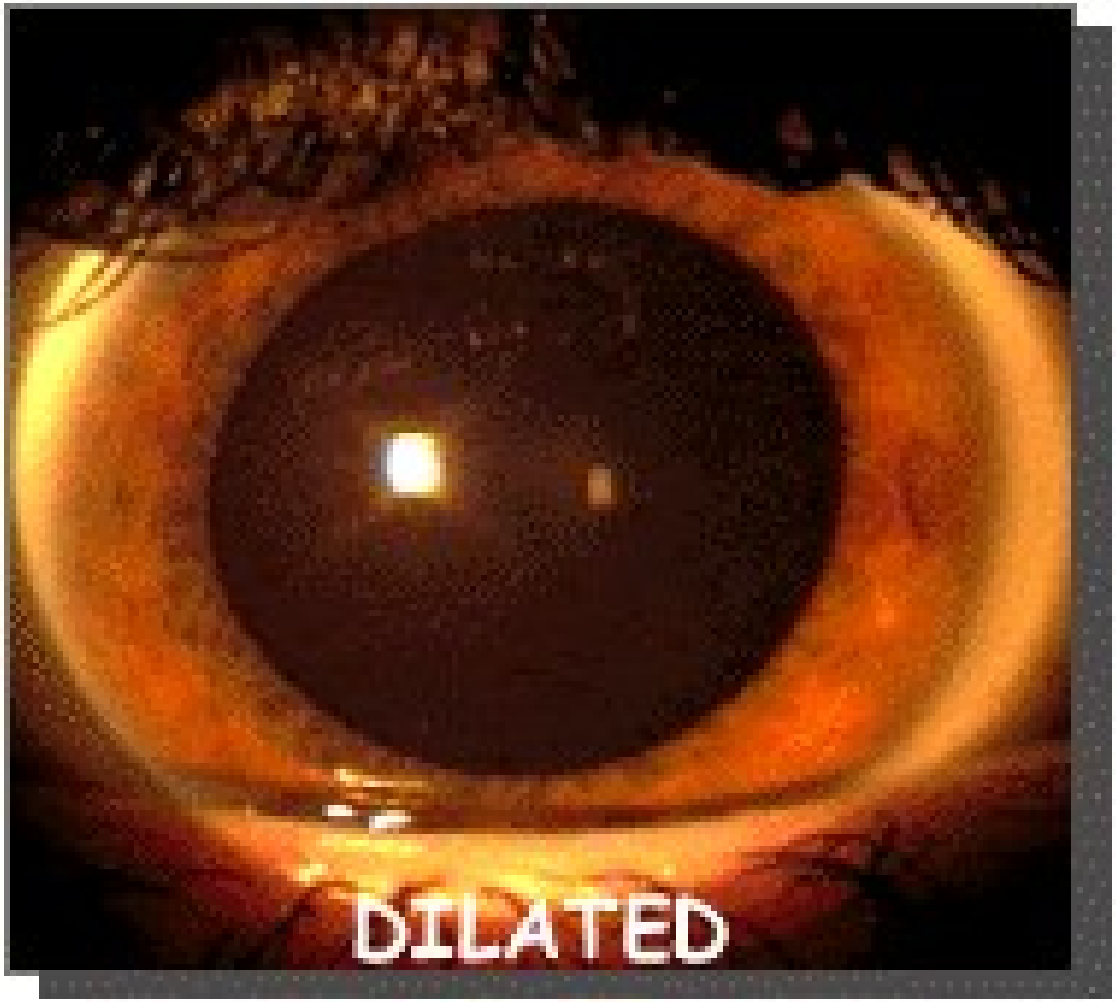

- Dilate pupil with short acting mydriatic e.g **tropicamide**
- Use **direct ophthalmoscope** → bright light
- Ask patient to fixate straight ahead at a target
- Examine right eye with right eye, left eye with left eye

- By this time, it is understood that the best way to examine an eye is in an ordered manner, gradually looking deeper into the eye having previously examined the more superficial parts.
- **What is unusual about the appearance of the pupil in this eye?**
- You will note that the eye is a **'quiet' eye without inflammation** → the cornea is clear in the central part and the iris is well seen. The patient does not complain of any pain. But the pupil area is white in colour.
- This is an opacity or clouding of the lens of the eye, situated behind the iris and involving the pupil area. This is a **cataract**.
- **Not all patients with a white pupil have cataract**, but in most patients, particularly in the older age group, this will be the diagnosis. If you see a patient with this appearance you should ask for specialist advice. A cataract can be removed surgically and sight restored.
- It is very important to refer any child with a white pupil to the eye specialist. Occasionally a child may have a serious tumour growing inside the eye which can look like a cataract when you examine the pupil area. Remember also that children may be born with cataracts - **congenital cataract.**

NORMAL DISC

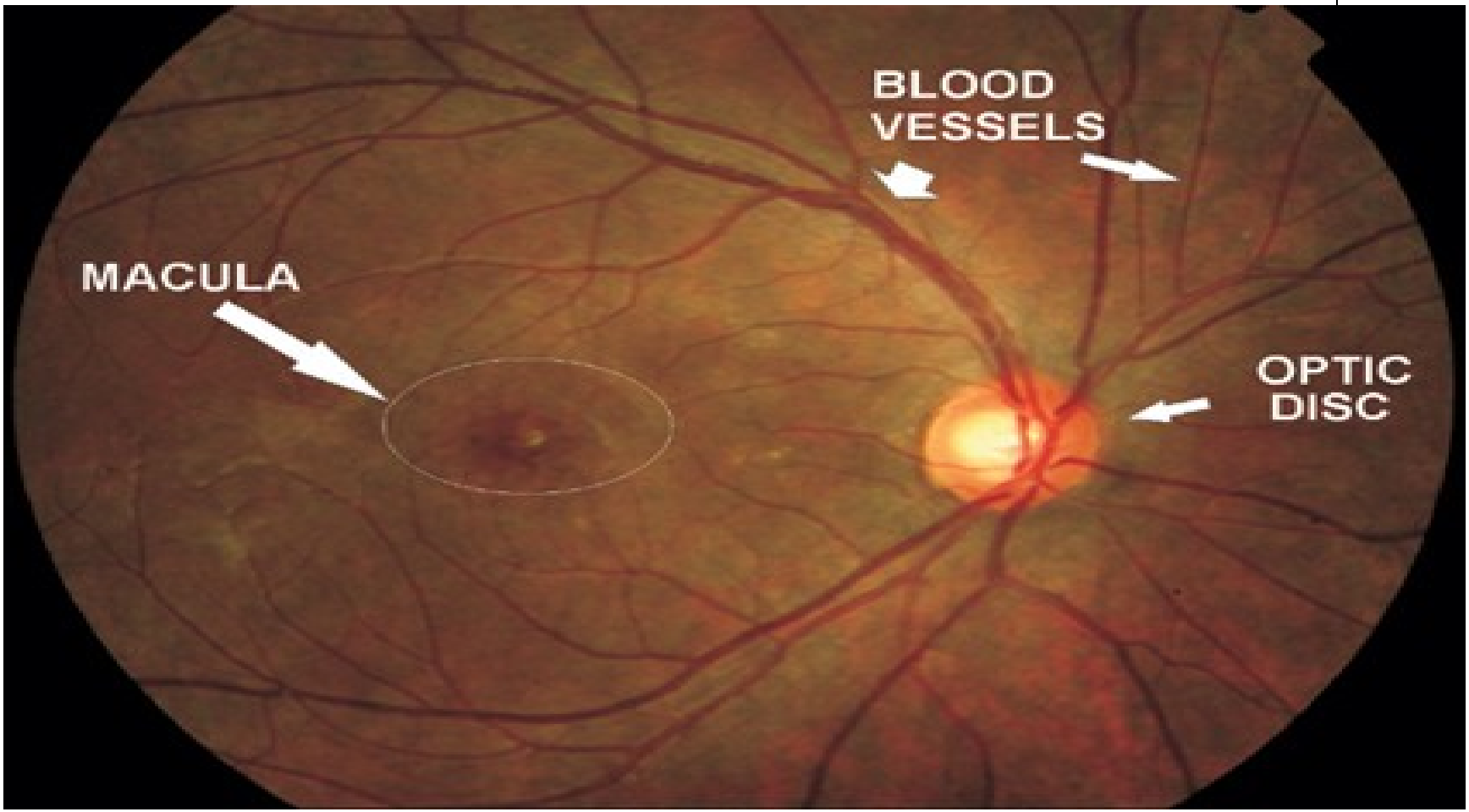

PAPILLOEDEMA

OPTIC ATROPHY

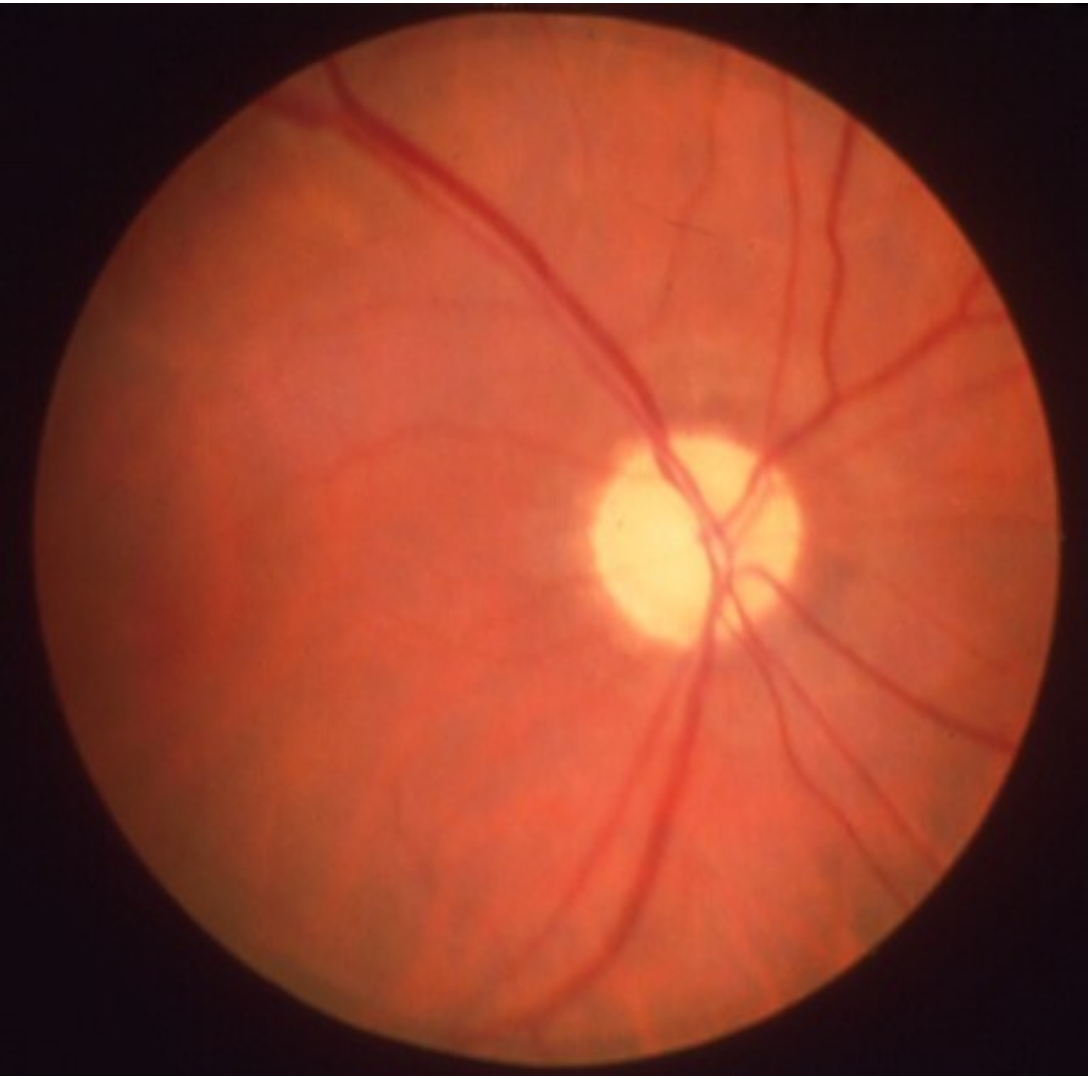

SUMMARY

- Good history taking
- Examine from **out going in**
- Start with **visual acuity**
- **Torch examination** for anterior segment
- Dilate pupil for **fundoscopy** (Direct ophthalmoscope used)

A RED EYE

- It means redness of the exposed white of the eye, i.e., the exposed conjunctiva and underlying sclera
- Main causes:
  - Infection
  - Inflammation
  - Trauma
  - Acute elevation of IOP
- Associated symptoms:
  - Discharge
  - Pain
  - Photophobia
  - Blurred vision

DIFFERENTIALS

- Deep red, sclera obscured → sub-conjunctival hemorrhage
- Diffuse bulbar and tarsal injection
  - Infective conjunctivitis, angle closure glaucoma, dry eyes reaction to topical medication
- Diffuse/ focal bulbar injection
  - Scleritis, chemical injury, endopthalmitis, pingueculae, pterygia
- Peri-limbal (ciliary) injection
  - Iritis, keratitis, corneal abrasion, corneal ulcer, corneal foreign body

TRAUMA

- Details of event
  - Was it due to blunt injury, a sharp object or a high-speed projectile
- Sub-conjunctival hemorrhage
  - Bright red (exposure to ambient Oxygen levels)
  - Association: trauma, spontaneous, systemic HTN, hemostatic disorders
- Corneal foreign bodies and abrasions → pain and epiphora
- Chemical injury → generalized or local conjunctival inflammation
  - Alkali burns → ischemic whitening

INFECTION

- Conjunctivitis
  - Discharge, mild discomfort (rather than pain)
  - Visual blur due to discharge is cleared by blinking
  - Bacterial infections → purulent discharge that may stick the lids together
  - Viral infections → watery discharge
  - Corneal involvement → photophobia and blurred vision
  - Chlamydial infection → chronically red eye

- Malpositon of the lids and blepharitis → secondary conjunctival inflammation due to irritation
  - Blepharitis → no discharge, associated with other skin diseases; lid irritation or itching

CONT.

- Corneal infection
  - Painful eye with reduced vision
  - Background history of contact lens?
- Endophthalmitis (intraocular infection)
  - Within days following intraocular surgery
  - Marked generalized conjunctival inflammation; painful eye with reduced vision
- Orbital cellulitis → medical emergency, visual may be lost rapidly due to optic nerve damage
  - swollen, erythematous lids
  - Chemotic, red conjunctiva (edematous)
  - Eye movements are reduced
  - Proptosis

OTHER SYMPTOMS

- Acute glaucoma → generalized red eye, corneal clouding, reduced vision and severe pain. Treat urgently.
- Sudden visual loss:
  - Uni-ocular: sudden clouding of the ocular media or by a problem with the retina or optic nerve
  - Determine onset, duration and progression to recovery
  - Associations: preceding visual symptoms or pain
    - Painful: Angle closure glaucoma uveitis, keratitis, orbital cellulitis, GCA, retrobulbar optic neuritis
    - Painless: raised ICP, Migraine, embolic retinal artery occlusion
  - Systemic conditions: HTN, DM
- Gradual vision loss:
  - Cataracts, chronic glaucoma

CONT.

- Diplopia:
  - Monocular → cataract
  - Binocular → EOM paresis due to disease of the 3rd, 4th or 6th cranial nerve

DIAGNOSTIC USE OF FLUORESCEIN

- Fluorescein has the property of absorbing light in the blue wavelength and emitting a green fluorescence.
- Application of fluorescein to the eye can identify **corneal abrasions** (where surface epithelial cells have been lost) and **leakage of aqueous humo**r from the eye where the cornea has been penetrated or a wound is unhealed.